

Genetic Identification of a Novel Truncating Mutation p.Thr738Argfs*28 in *XPC* Gene in a Family from Iraq

Fatemeh Yadegari¹, Aseel Rashid Abed², Widad Yadallah Abd Ali², Haider Hamza Al-Abedi², Shiva Zarinfam¹, Rabbie Hanna², Fawaz Al-Alloosh², Solaleh Aminian¹, Keivan Majidzadeh-A^{1*}

¹ Genetics Department, Breast Cancer Research Center, Motamed Cancer Institute, ACECR, Tehran, Iran

² Warith International Cancer Institute, Karbala, Iraq

*Corresponding Author: Keivan Majidzadeh-A, Genetics Department, Breast Cancer Research Center, Motamed Cancer Institute, ACECR, Tehran, Iran, E-mail: kmajidzadeh@acecr.ac.ir

Submitted: July 01, 2025

Revised: October 14, 2025

Accepted: December 07, 2025

e-Published: December 10, 2025

Keywords:

Xeroderma pigmentosum (XP)

Genotyping

Pathogenic mutation

Homology modeling

Genetic counseling

Introduction: Xeroderma pigmentosum (XP) is a rare, autosomal recessive disorder characterized by extreme sensitivity to UV-induced DNA damage, resulting in symptoms such as severe sunburn, freckles, dry skin, premature skin aging, and, occasionally, neurological symptoms.

Case Report: The study focuses on a 6-year-old girl with XP symptoms since age three. Genotyping was performed to identify the responsible mutation, followed by molecular modeling to predict the structural consequences of the amino acid substitution.

Results: The identified variant is a novel homozygous frameshift mutation *XPC*: c.2213_2216del (p.Thr738Argfs*28) in exon 12, corresponding to genomic coordinates (hg19/GRCh37) chr3:14190347 CTCTG>C based on the canonical transcript NM_004628.5. This variant is predicted to cause XP. Homology modeling reveals that this mutation deletes a critical region at the extreme COOH terminus of the XPC protein, which is crucial for its interaction with TFIIH and CETN2. While the mutant protein can still interact with DNA, it loses its ability to interact with TFIIH and CETN2, leading to loss of protein function.

Conclusions: This study expands the spectrum of mutations observed in the *XPC* gene by identifying a new pathogenic mutation. The results of this study highlight the importance of medical and genetic counseling in protecting future generations against genetic disease.

Copyright © 2025 Yadegari et al. Published by Breast Cancer Research Center, ACECR. This work is licensed under a Creative Commons Attribution - NonCommercial 4.0 International License (<https://creativecommons.org/licenses/by-nc/4.0/>) non-commercial uses are permitted, provided the original work is properly cited.

INTRODUCTION

Xeroderma pigmentosum (XP) is a rare genetic disorder inherited in an autosomal recessive manner. It is characterized by extreme sensitivity to sunlight and other light sources, leading to redness and sunburn on sun-exposed areas from birth (50%), freckles before age 2, skin hyper- and hypopigmentations, loss of vision, and damage to the eyelids, lips, and tip of the tongue. Neurological deficits such as dysphagia, sensory neural hearing loss, ataxia, intellectual disability, muscle weakness,

and premature death have been seen in 25% of patients with XP. They are 10000 times more likely to develop skin cancers, including basal cell carcinoma, squamous cell carcinoma, and melanoma, and 2000 times more likely to develop ocular cancers. These cancers are typically present before age 10 [1-6]. This disease results from a faulty nucleotide excision repair (NER) system, which corrects a wide range of DNA lesions, including helix-distorting DNA damage and bulky adducts. The NER pathway employs two mechanisms to remove DNA lesions: transcription-

Table 1. Comparison of clinical features of syndromes associated with NER deficiencies.

	XP	XP with neurologic changes	De Sanctis – Cacchio ne syndro me	TRICHOTHIO- DYSTROPHY (TTD)	COCKAYN E SYNDROM E (CS)	XP/CS COMPLEX	Cerebro-oculo- facio-skeletal (COFS) syndrome	UV-sensitive syndrome
Skin								
Skin sun sensitivity	+	+	+	±	+	+	+	+
Abnormal skin pigmentation	+	+	+	-	-	+	-	+
Sunlight-induced skin cancer	+	+	+	-	-	+	-	-
Eyes								
Photophobia	+	+	+	±	+	+	-	-
Conjunctival growths	+	+	+	-	-	+	-	-
Congenital cataracts	-	-	-	+	+	-	+	-
Pigmentary retinal degeneration	-	-	-	-	+	+	+	-
Somatic								
Short stature	-	±	+	+	+	+	+	-
Immature sexual development	-	-	+	±	+	+	-	-
Nervous system								
Deafness	-	+	+	-	+	+	+	-
Mental retardation	-	+	+	+	+	+	+	-
Primary neuronal degeneration	-	+	+	-	-	-	?	-
Progressive neurological degeneration	-	+	+	Unknown (not reported)		+	+	-
Demyelination	-	-	-	+	+	+	+	-
Microcephaly	-	+	+	+	+	+	+	-
Calcification	-	-	-	±	+	+	+	-
Cerebral atrophy	-	+	+	±	+	+	+	-
Spasticity	-	±	+	±	+	+	+	-
Inheritance	AR	AR	AR	AR	AR	AR	AR	AR

	XP	XP with neurologic changes	De Sanctis – Cacchione syndrome	TRICHOThIO-DYSTROPHY (TTD)	COCKAYNE SYNDROME (CS)	XP/CS COMPLEX	Cerebro-oculo-facio-skeletal (COFS) syndrome	UV-sensitive syndrome
Molecular defect	<i>XPA, XP-B, XP-C, XP-D, XP-E, XP-F, XP-G</i>	<i>XP-A, XP-B, XP-D, XP-F, XPG</i>	<i>XP-A, XP-D, CS-B</i>	<i>XPB, XPD, TTDA, TTDNI</i>	<i>CSA, CSB</i>	<i>XPB, XPD, XPG</i>	<i>CSB, ERCC1, XPD, XPG</i>	<i>CSA, CSB or UVSSA/KIAA1530</i>

coupled repair (TC-NER) and global genome repair (GG-NER). TC-NER specifically detects and eliminates damage from the transcribed strand of active genes, while GG-NER repairs DNA lesions throughout the entire genome [7-9]. Except for the mode of DNA damage recognition, these mechanisms are almost identical. In TC-NER, transcription-blocking DNA lesions are identified by Cockayne Syndrome B (CSB) and Cockayne Syndrome A (CSA) proteins, while in GG-NER, DNA damage is recognized by the XPC protein complexed with the human homolog of Rad23-B (hHR23B) and CETN2. XP is caused by mutations in one of several genes involved in the nucleotide excision repair (NER) pathway, including *DDB2* (*XP-E*), *ERCC1*, *ERCC2* (*XP-D*), *ERCC3* (*XP-G*), *ERCC4* (*XP-F*), *ERCC5* (*XP-B*), *XPC*, *XPA*, and *POLH* (*XP-V*). While most groups exhibit nucleotide excision repair (NER) deficiency and can present with or without neurological abnormalities, the variant form (*XP-V*, caused by *POLH* mutations) typically shows milder features, limited to cutaneous photosensitivity and a predisposition to skin cancer. In addition to the heterogeneity within XP itself, defects in several of the same NER-related genes can give rise to other overlapping syndromes with XP-like features. A detailed comparison of clinical features across XP complementation groups and related syndromes is described below and summarized in Table 1.

Cockayne syndrome (CS), cerebro-oculo-facio-skeletal (COFS) syndrome, trichothiodystrophy (TTD), and UV-sensitive syndrome are diseases with mutations in some of the same genes as those involved in XP [10, 11]. De Sanctis–Cacchione syndrome (DSC) represents the most severe form of XP

characterized by manifestations such as dwarfism, mental disabilities, and immature sexual development [12-14]. The severity of this syndrome depends on the extent of DNA repair damage [15, 16]. Mutations in the *CSA* and *CSB* genes cause CS. This disease is characterized by skin photosensitivity, but unlike XP, it does not increase the susceptibility to skin cancer. Individuals with CS may experience cachectic dwarfism and progressive neurological abnormalities, including microcephaly, retinal atrophy, sensorineural deafness, and difficulty walking and feeding [17-19]. Another disorder, trichothiodystrophy (TTD), a TC-NER-specific disorder, is caused by mutations in the *XPB*, *XPD*, *TTDA*, and *TTDNI* genes. TTD shares many symptoms with Cockayne syndrome but presents additional features such as sulfur-deficient brittle hair, nails, and scaly skin [20-23]. Mutations in the *XPB* and *XPD* genes, subunits of the TFIIH complex, can result in XP, TTD, or a combination of both (XP-CS) [22].

In contrast to XP, individuals with CS and TTD do not have an increased risk of skin cancer or pigmentary abnormalities. Syndromes associated with NER deficiency exhibit similar clinical signs, including photosensitivity and mental problems, making it challenging to differentiate between them. In addition to NER-related disorders, other conditions may present with abnormal pigmentation that can mimic XP or related syndromes. Peutz-Jeghers syndrome, Leopard syndrome, and Carney complex are autosomal dominant lentiginoses that are not directly associated with sun exposure. However, they exhibit a common abnormal pigmentation feature, similar to conditions such as XP, CS, DCS, and the XP/CS

complex [24]. This study presents the clinical and genetic features of a 6-year-old Iraqi girl who exhibited XP-like features.

CASE REPORT

Clinical History

A 6-year-old girl with clinical features indicative of XP was referred to the Alwarith Cancer Institute for genetic counseling. These features included extreme sensitivity to sunlight, freckles in sun-exposed areas, dry skin, and photophobia. After obtaining written informed consent from the proband's parents, pedigree information, including consanguinity, affected family members, associated diseases, and family history, was collected through interviews with both parents and physical examination of the proband and other children in the family (Figure 1). All data were handled confidentially in accordance with institutional guidelines.

Whole exome sequencing (WES)

DNA was extracted from peripheral blood leukocytes using the Blood Mini Kit (Zista Gene, Iran) according to the manufacturer's instructions. The DNA obtained from the proband underwent whole-exome sequencing (WES) on the BGISEQ-500 system, using 100-bp paired-end reads. After quality control (QC), sequence reads were aligned to the GRCh37/hg19 build of the human reference genome using BWA-MEM. Variant filtering was then performed to

identify sequence variants associated with the proband's phenotype, focusing on allele frequency and predicted pathogenicity, particularly in genes associated with dermatological or DNA repair disorders.

Homology modeling

Currently, no experimentally determined 3D crystal structure of the human XPC protein is available. To address this, we employed homology modeling, a computational approach that predicts a protein's 3D structure using the known structure of a homologous protein as a template. For this purpose, we used the yeast Rad4–Rad23 complex bound to DNA (PDB ID: 2QSH) (Min & Pavletich, 2007), as yeast Rad4 shares approximately 40% sequence similarity with human XPC. This structure served as a template to construct a model of the human XPC–RAD23B protein bound to DNA using MODELLER version 9.15.

RESULTS

Clinical Findings and Genetic Study

We present the case of a six-year-old girl, born to a consanguineous marriage, experiencing severe skin sensitivity to sunlight. This condition has led to burns, dry skin, and multiple freckles on her face, hands, arms, legs, abdomen, and upper chest. The cutaneous manifestations observed in our patient, including freckling, poikiloderma, and actinic damage, are similar to some of the representative clinical images of XP available on the DermIS – Dermatology Online

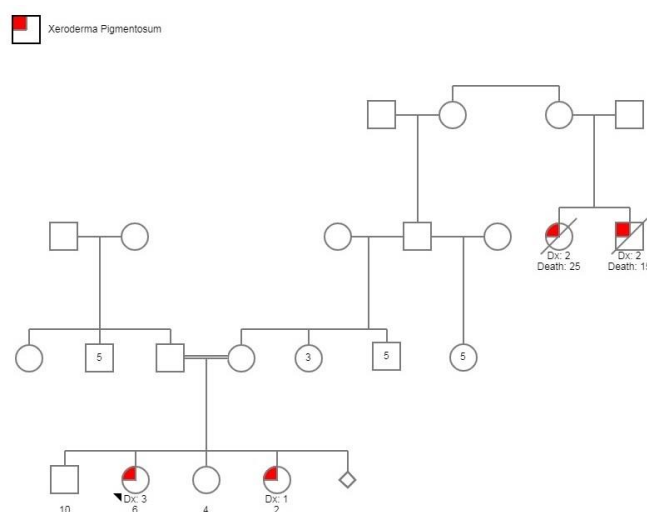


Figure 1. The pedigree information of this family.

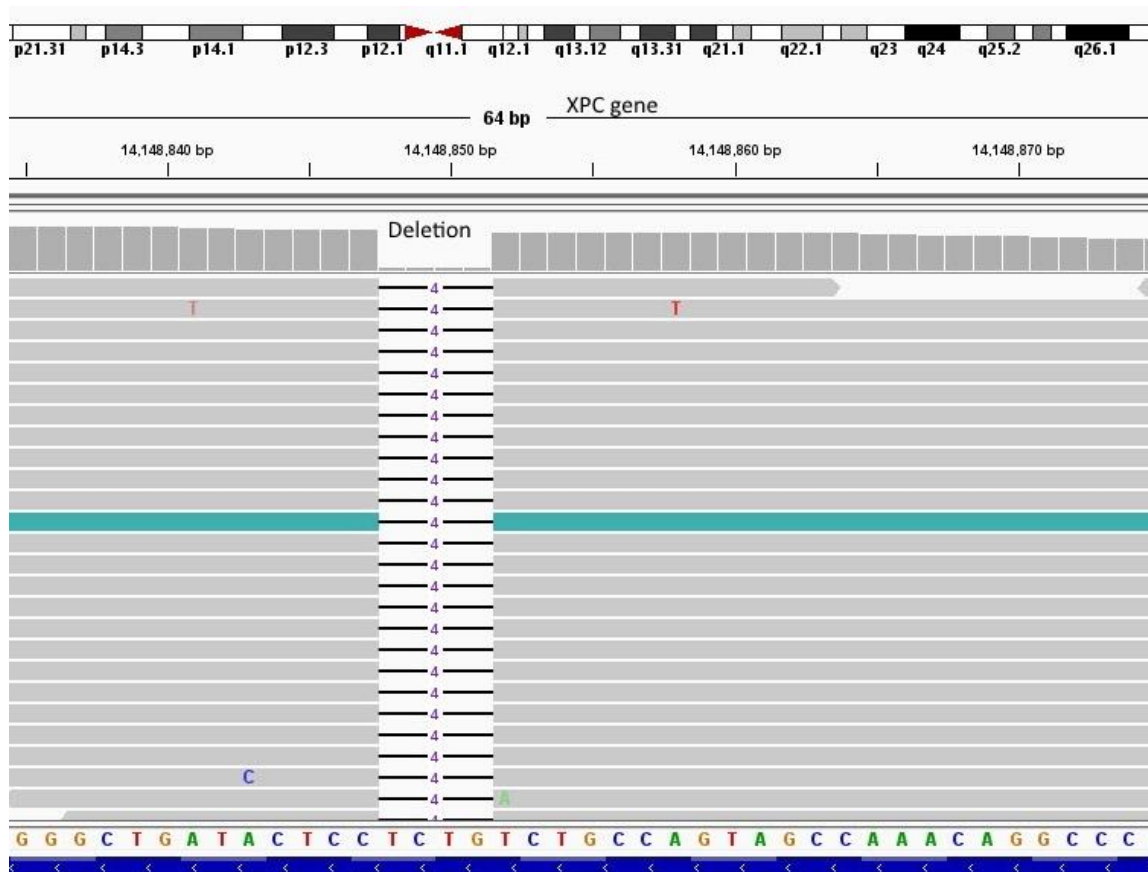


Figure 2. Identification of a novel homozygous frameshift deletion (c.2213_2216del, p.Thr738Argfs*28, NM_004628.5, hg19: chr3:14190347 CTCTG>C) using whole exome sequencing.

Atlas (Diepgen TL, Yihune G et al., published online at:

<https://www.dermis.net/dermisroot/en/40662/diagnose.htm>). These symptoms have been present since she was three years old. The child has also exhibited ocular symptoms such as photophobia and red eyelids. These characteristics were all suggestive of Xeroderma Pigmentosum, an autosomal recessive disorder. However, no signs of skin malignancy and neurological involvement, including microcephaly, retinal atrophy, sensorineural deafness, and walking and feeding difficulties, have been observed. WES was performed on the proband's genomic DNA to elucidate the genetic basis of these symptoms further. A novel homozygous frameshift deletion in exon 12 of the *XPC* gene (c.2213_2216del, p.Thr738Argfs*28, NM_004628.5, hg19: chr3:14190347 CTCTG>C) was detected (Figure 2). This deletion changes threonine to arginine at codon 738, creating a premature stop codon and resulting in truncation of the translated protein at codon 765

(p.Thr738ArgfsX28).

Homology modeling

The carboxy-terminal domain of the XPC has been shown to have critical interactions with damaged DNA (residues 607-742), RAD23B (residues 496-734), CETN2 (residues 847-866), and TFIIH (residues 816-940) [25-29]. CETN2 and RAD23B have been reported to enhance the stability and DNA damage-recognition sensitivity of XPC [26, 30]. According to the 3D structural model constructed in this study, the truncated protein (p.Thr738Argfs*28) lacks the essential residues required for interaction with CETN2 (residues 847-866) and TFIIH (residues 816-940). However, it retains its ability to interact with DNA and RAD23B, as illustrated in Figure 3.

CONCLUSIONS AND DISCUSSION

XP is a hereditary disease with varying incidence across regions, affecting approximately 1 in 100,000 individuals in the United States and Europe, 1 in 20,000 to 100,000 in Japan, and 1 in 10,000 to 50,000

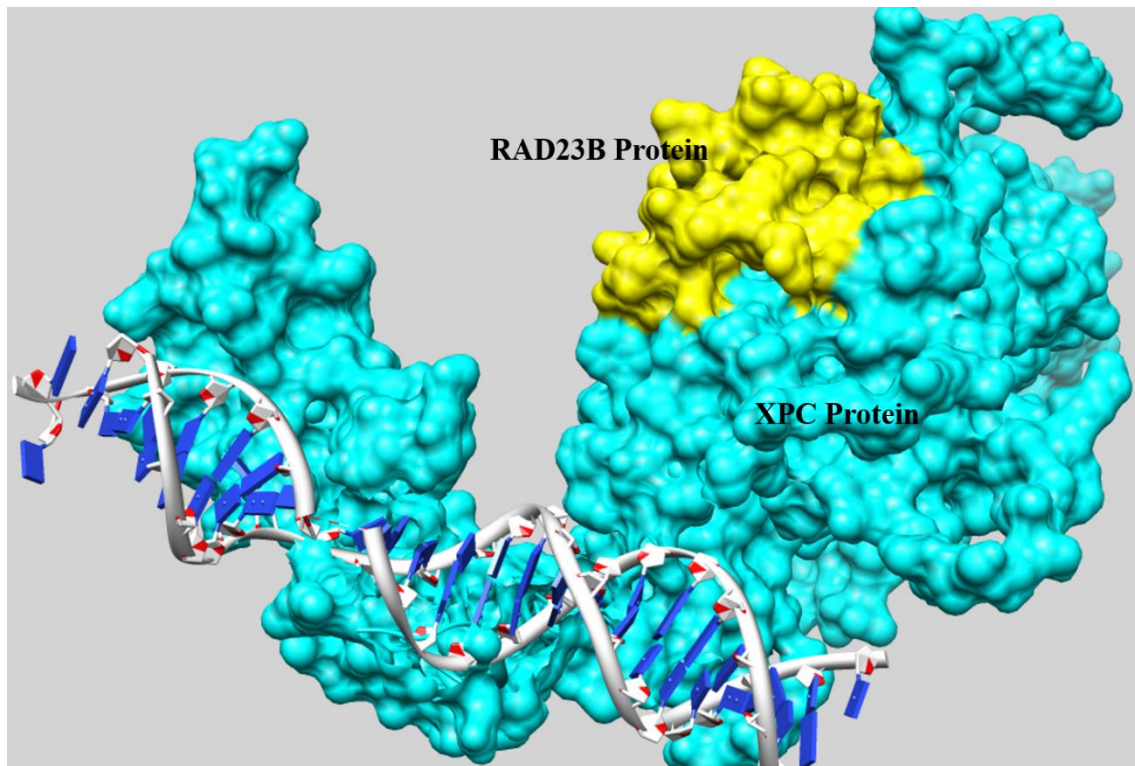


Figure 3. Structural model of the putative XPC in complex with RAD23B and DNA.

in North Africa and the Middle East. This condition arises from mutations in the NER pathway, including XPA-XPG and XPV [31, 32]. In North Africa, Europe, and the Middle East, mutations in the *XPC* gene are the most commonly observed cause of XP [33]. Conversely, in Japan, XPA mutations are the predominant cause of the disease [31]. Various types of mutations have been identified in the *XPC* gene, although most of them are frameshift or nonsense mutations. For example, a Chinese XP-C patient was found to carry two novel compound heterozygous *XPC* variants and also presented with an ovarian teratoma, illustrating that XP-C can sometimes affect internal organs [34]. In another report, a 19-year-old XP patient harbored a 13-bp deletion and a splice-site mutation in *XPC* [35]. Additionally, a consanguineous Pakistani family was found to carry a novel protein-truncating mutation (c.291dupT; p.Asp98*) in *XPC*, resulting in a truncated protein and confirming the autosomal recessive inheritance pattern [36]. A homozygous missense mutation (c.919C>T; p.Arg307Trp) was reported in a family with multiple melanoma cases, and the *MC1R* p.I155T variant

appeared to modify the severity of the disease [37]. Additionally, a 4-year-old Korean boy with an *XPC* splice site mutation presented with typical cutaneous XP manifestations as well as autistic features and metabolic abnormalities, including hypoglycinemia [38].

In this case study, we present a 6-year-old girl who developed pigmented lesions on sun-exposed areas of her skin at age 3. Analysis revealed a homozygous frameshift mutation in exon 12 of the *XPC* gene (c.2213_2216del, p.Thr738Argfs*28, NM_004628.5, hg19: chr3:14190347 CTCTG>C)

Based on the clinical and molecular findings, XP was diagnosed in this case. The homozygous deletion variant (Thr738Argfs*28) found in our case created a premature termination codon (PTC) that reduced the length of the XPC protein from 940 to 765 residues. mRNA transcripts containing a PTC resulting from DNA mutations or RNA processing errors are typically recognized and degraded via nonsense-mediated mRNA decay (NMD) [39]. Generally, mRNA transcripts with premature termination codons within 50–55 nucleotides upstream of an exon-exon

junction are subject to degradation by NMD [40, 41]. However, exceptions to this rule have been reported [42], suggesting that a larger proportion of transcripts with premature termination codons may potentially undergo degradation via NMD [43]. Based on the 50–55-nucleotide rule, it is likely that NMD would target and remove the mRNA containing the Thr738Argfs*28 mutation, leading to loss of gene function. If no NMD occurs, it produces a truncated protein at the extreme C-terminus of XPC (Thr738Argfs*28). The functional consequences of such truncation mutations depend on the extent of protein loss. As illustrated in Figure 3, the truncation mutation (Thr738Argfs*28) identified in this study does not appear to affect the interaction between XPC and DNA or between XPC and HR23B. However, this specific mutation disrupts XPC's binding to CETN2 and TFIIF. Previous studies have demonstrated that human cells lacking XPC-TFIIF interaction exhibit a complete deficiency in NER [29]. Therefore, if the XPC protein carrying this mutation (Thr738Argfs*28) had been expressed, it would likely be non-functional.

Genetic testing plays a key role in high-risk populations, especially in regions with frequent consanguineous marriages. Early identification of pathogenic *XPC* variants can help families make informed reproductive decisions and implement preventive measures, thereby reducing the risk of affected children in future generations.

The diagnosis can be made before birth by chorionic villus sampling (CVS) and amniocentesis, to identify related mutations. While there is no cure for XP after birth, adopting sun protection measures can reduce skin and eye problems associated with XP. Photoprotection actions, including sun-protective clothing, sunglasses, face shields, staying in the shade, and minimizing outdoor activities during midday, can effectively reduce skin damage caused by ultraviolet radiation. Topical retinoids and vitamin D supplements may also help reduce problems associated with XP [44]. To facilitate education on sun protection methods, we have compiled a catalog of informative materials in both English and Arabic, offering parents quick and easy-to-follow instructions. The English version of these instructions,

in the form of a brochure complete with photos and detailed descriptions of recommendations, is attached to this study as supplementary material (Brochure S1).

CONFLICT OF INTEREST

The authors declare that they have no conflict of interest.

ACKNOWLEDGEMENTS

We thank the patient's family for their participation in this study

ETHICS APPROVAL

Not applicable.

REFERENCES

1. Jeppesen DK, Bohr VA, Stevnsner T. DNA repair deficiency in neurodegeneration. *Prog Neurobiol.* 2011;94(2):166–200. doi: 10.1016/j.pneurobio.2011.04.013
2. Lehmann A. Three complementation groups in Cockayne syndrome. *Mutat Res.* 1982;106(2):347–356.
3. Subba Rao K. Mechanisms of disease: DNA repair defects and neurological disease. *Nat Clin Pract Neurol.* 2007;3(3):162–172. doi: 10.1038/ncpneuro0427
4. Rass U, Ahel I, West SC. Defective DNA repair and neurodegenerative disease. *Cell.* 2007;130(6):991–1004. doi: 10.1016/j.cell.2007.08.043
5. Tamura D, DiGiovanna JJ, Khan SG, Kraemer KH. Living with xeroderma pigmentosum: comprehensive photoprotection for highly photosensitive patients. *Photodermatol Photoimmunol Photomed.* 2014;30(2–3):146–152. doi: 10.1111/phpp.12088
6. Kraemer KH, Lee MM, Scotto J. Xeroderma pigmentosum: cutaneous, ocular, and neurologic abnormalities in 830 published cases. *Arch Dermatol.* 1987;123(2):241–250.
7. Marteijn JA, Lans H, Vermeulen W, Hoeijmakers JHJ. Understanding nucleotide excision repair and its roles in cancer and ageing. *Nat Rev Mol Cell Biol.* 2014;15(7):465–481. doi: 10.1038/nrm3822
8. Sugasawa K. Molecular mechanisms of DNA damage recognition for mammalian nucleotide excision repair. *DNA Repair (Amst).* 2016;44:110–117. doi: 10.1016/j.dnarep.2016.05.002
9. Lehmann A, Kirk-Bell S, Arlett C, Paterson M, Lohman P, de Weerd-Kastelein E, et al. Xeroderma pigmentosum cells with normal levels of excision repair have a defect in DNA synthesis after UV-irradiation. *Proc Natl Acad Sci*

- U S A. 1975;72(1):219–223. doi: 10.1073/pnas.72.1.219
10. Suzumura H, Arisaka O. Cerebro-oculo-facio-skeletal syndrome. In: Diseases of DNA Repair. 2010. p. 210–214.
 11. Moriwaki SI. Hereditary disorders with defective repair of UV-induced DNA damage. *Jpn Clin Med.* 2013;4:25–35. doi: 10.4137/JCM.S10730
 12. Cleaver JE, Charles WC, Kong SH. Efficiency of repair of pyrimidine dimers and psoralen monoadducts in normal and xeroderma pigmentosum human cells. *Photochem Photobiol.* 1984;40(5):621–629. doi: 10.1111/j.1751-1097.1984.tb04636.x
 13. Cleaver JE, Thomas GH. Rapid diagnosis of sensitivity to ultraviolet light in fibroblasts from dermatologic disorders, with particular reference to xeroderma pigmentosum. *J Invest Dermatol.* 1988;90(4):467–471. doi: 10.1111/1523-1747.ep12460833
 14. Mittal H, Mehndiratta S, Kaushik JS, Godbole T. De Sanctis–Cacchione syndrome. *Indian J Dermatol Venereol Leprol.* 2013;79:849. doi: 10.4103/0378-6323.120759
 15. Caldas ALR, Rodrigues MM. De Sanctis–Cacchione syndrome in a female infant: case report. *An Bras Dermatol.* 2013;88:979–981. doi: 10.1590/abd1806-4841.20132578
 16. Hessel A, Siegle RJ, Mitchell DL, Cleaver JE. Xeroderma pigmentosum variant with multisystem involvement. *Arch Dermatol.* 1992;128(9):1233–1237.
 17. Nance MA, Berry SA. Cockayne syndrome: review of 140 cases. *Am J Med Genet.* 1992;42(1):68–84. doi: 10.1002/ajmg.1320420114
 18. Soffer D, Grotzky HW, Rapin I, Suzuki K. Cockayne syndrome: unusual neuropathological findings and review of the literature. *Ann Neurol.* 1979;6(4):340–348. doi: 10.1002/ana.410060408
 19. Spivak G. The many faces of Cockayne syndrome. *Proc Natl Acad Sci U S A.* 2004;101(43):15273–15274. doi: 10.1073/pnas.0407402101
 20. DiGiovanna JJ, Kraemer KH. Shining a light on xeroderma pigmentosum. *J Invest Dermatol.* 2012;132(3):785–796. doi: 10.1038/jid.2011.426
 21. Nakabayashi K, Amann D, Ren Y, Saarialho-Kere U, Avidan N, Gentles S, et al. Identification of C7orf11 (TTDN1) gene mutations and genetic heterogeneity in nonphotosensitive trichothiodystrophy. *Am J Hum Genet.* 2005;76(3):510–516. doi: 10.1086/428650
 22. Stefanini M, Botta E, Lanzafame M, Orioli D. Trichothiodystrophy: from basic mechanisms to clinical implications. *DNA Repair (Amst).* 2010;9(1):2–10. doi: 10.1016/j.dnarep.2009.10.003
 23. Price VH, Odom RB, Ward WH, Jones FT. Trichothiodystrophy: sulfur-deficient brittle hair as a marker for a neuroectodermal symptom complex. *Arch Dermatol.* 1980;116(12):1375–1384.
 24. Lehmann AR, McGibbon D, Stefanini M. Xeroderma pigmentosum. *Orphanet J Rare Dis.* 2011;6:70. doi: 10.1186/1750-1172-6-70
 25. Uchida A, Sugawara K, Masutani C, Dohmae N, Araki M, Yokoi M, et al. The carboxy-terminal domain of the XPC protein plays a crucial role in nucleotide excision repair through interactions with transcription factor IIH. *DNA Repair (Amst).* 2002;1(6):449–461. doi: 10.1016/S1568-7864(02)00044-8
 26. Popescu A, Miron S, Blouquit Y, Duchambon P, Christova P, Craescu CT. Xeroderma pigmentosum group C protein possesses a high affinity binding site to human centrin 2 and calmodulin. *J Biol Chem.* 2003;278(41):40252–40261. doi: 10.1074/jbc.M304278200
 27. Nishi R, Okuda Y, Watanabe E, Mori T, Iwai S, Masutani C, et al. Centrin 2 stimulates nucleotide excision repair by interacting with xeroderma pigmentosum group C protein. *Mol Cell Biol.* 2005;25(13):5664–5674. doi: 10.1128/MCB.25.13.5664-5674.2005
 28. Thompson JR, Ryan ZC, Salisbury JL, Kumar R. The structure of the human centrin 2–xeroderma pigmentosum group C protein complex. *J Biol Chem.* 2006;281(27):18746–18752. doi: 10.1074/jbc.M601832200
 29. Bunick CG, Miller MR, Fuller BE, Fanning E, Chazin WJ. Biochemical and structural domain analysis of xeroderma pigmentosum complementation group C protein. *Biochemistry.* 2006;45(50):14965–14979. doi: 10.1021/bi061623m
 30. Araki M, Masutani C, Takemura M, Uchida A, Sugawara K, Kondoh J, et al. Centrosome protein centrin 2/caltractin 1 is part of the xeroderma pigmentosum group C complex that initiates global genome nucleotide excision repair. *J Biol Chem.* 2001;276(22):18665–18672. doi: 10.1074/jbc.M101976200
 31. Hirai Y, Kodama Y, Moriwaki SI, Noda A, Cullings HM, MacPhee DG, et al. Heterozygous individuals bearing a founder mutation in the XPA DNA repair gene comprise nearly 1% of the Japanese population. *Mutat Res.* 2006;601(1–2):171–178. doi: 10.1016/j.mrfmmm.2006.08.003
 32. Moriwaki SI, Kraemer KH. Xeroderma pigmentosum—bridging a gap between clinic and laboratory. *Photodermatol Photoimmunol Photomed.* 2001;17(2):47–54. doi: 10.1034/j.1600-0781.2001.170202.x
 33. Soufir N, Ged C, Bourillon A, Austerlitz F, Chemin C, Sary A, et al. A prevalent mutation with founder effect in xeroderma pigmentosum group C from north Africa. *J Invest Dermatol.* 2010;130(6):1537–1542. doi: 10.1038/jid.2009.420

34. Tang L, Cheng Y, Zhang Y, Ran D, Yang C, Gao M, et al. Novel compound heterozygous variants in the XPC gene identified in a Chinese xeroderma pigmentosum group C patient with ovarian teratoma. *J Dermatol*. 2018;45(11):e300–e301. doi: 10.1111/1346-8138.14587
35. Rivera-Begeman A, McDaniel LD, Schultz RA, Friedberg EC. A novel XPC pathogenic variant detected in archival material from a patient diagnosed with xeroderma pigmentosum: a case report and review of the genetic variants reported in XPC. *DNA Repair (Amst)*. 2007;6(1):100–114. doi: 10.1016/j.dnarep.2006.08.008
36. Ali MZ, Blatterer J, Khan MA, Schaflinger E, Petek E, Ahmad S, et al. Identification of a novel protein truncating mutation p.Asp98* in XPC associated with xeroderma pigmentosum in a consanguineous Pakistani family. *Mol Genet Genomic Med*. 2020;8(2):e1060. doi: 10.1002/mgg3.1060
37. Leidenz FAB, Bittencourt FV, Braga WG, de Sá Araújo EM, Gomes CC, de Fátima Bernardes V, et al. Familial melanoma phenotype with xeroderma pigmentosum group C (XP-C) genotype: the putative role of MC1R polymorphism as modifier. *Dermatol Pract Concept*. 2024;14(1):e2024050. doi: 10.5826/dpc.1401a50
38. Khan SG, Levy HL, Legerski R, Quackenbush E, Reardon JT, Emmert S, et al. Xeroderma pigmentosum group C splice mutation associated with autism and hypoglycinemia. *J Invest Dermatol*. 1998;111(5):791–796. doi: 10.1046/j.1523-1747.1998.00354.x
39. Schell T, Kulozik AE, Hentze MW. Integration of splicing, transport and translation to achieve mRNA quality control by the nonsense-mediated decay pathway. *Genome Biol*. 2002;3(3):reviews1006. doi: 10.1186/gb-2002-3-3-reviews1006
40. Thermann R, Neu-Yilik G, Deters A, Frede U, Wehr K, Hagemeyer C, et al. Binary specification of nonsense codons by splicing and cytoplasmic translation. *EMBO J*. 1998;17(12):3484–3494. doi: 10.1093/emboj/17.12.3484
41. Zhang J, Sun X, Qian Y, LaDuca JP, Maquat LE. At least one intron is required for the nonsense-mediated decay of triosephosphate isomerase mRNA. *Mol Cell Biol*. 1998;18(9):5272–5283. doi: 10.1128/MCB.18.9.5272
42. Frischmeyer PA, Dietz HC. Nonsense-mediated mRNA decay in health and disease. *Hum Mol Genet*. 1999;8(10):1893–1900. doi: 10.1093/hmg/8.10.1893
43. Savas S, Tuzmen S, Ozcelik H. Human SNPs resulting in premature stop codons and protein truncation. *Hum Genomics*. 2006;2(5):274–286. doi: 10.1186/1479-7364-2-5-274
44. Leung AKC, Barankin B, Lam JM, Leong KF, Hon KL. Xeroderma pigmentosum: an updated review. *Drugs Context*. 2022;11:2022-1-2. doi: 10.7573/dic.2022-1-2